

IV. c. Esophagus (cont'd)

3. Structure

- Has both smooth & skeletal muscle (all involuntary) - peristalsis
- Cardiac sphincter at exit into stomach
 - Circular muscle layer of muscularis externa is thick
 - Prevents reflux from stomach
 - If fails to close (e.g. due to hiatal hernia)
 - GERD (gastroesophageal reflux disease)

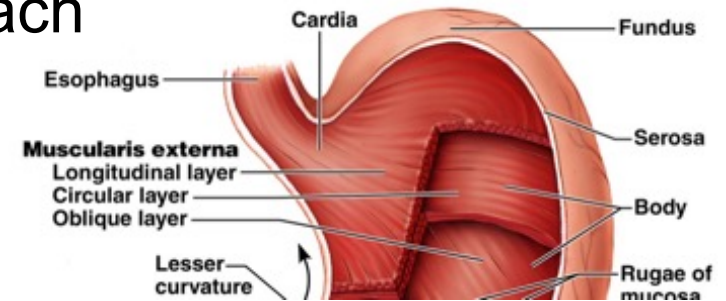


Fig. 23.17

